

# Dentistry Clinical

## Engineering the solution

Harry Shiers presents a case report on the restoration of a unilateral posterior maxilla with an implant-retained bridge

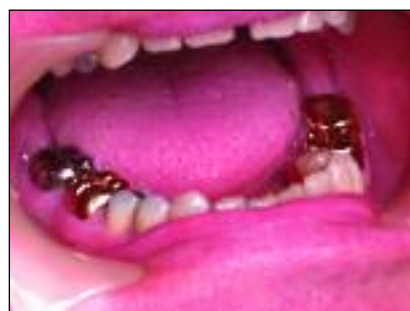

Figure 1: The patient demonstrated fairly heavily restored dentition

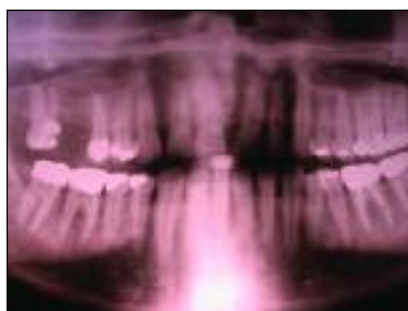

Figure 2: The DPT of the patient at presentation. The periapical radiolucency associated with the mesio-buccal and palatal roots may be seen

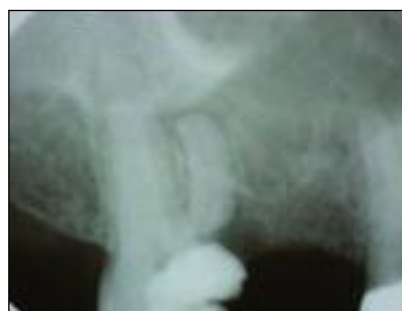

Figure 3: A digital periapical image of the upper right second molar and upper right second pre-molar, where the extent of the decay in the maxillary second molar is seen more clearly

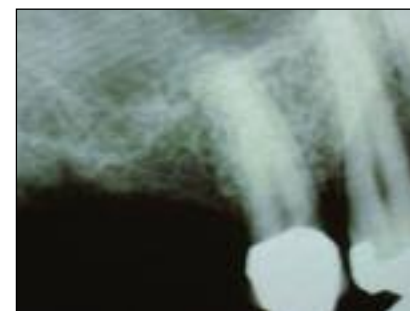


Figure 4: Two further periapical radiographs were taken prior to the selection of the implants

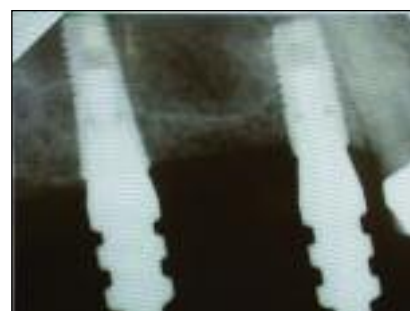

Figure 5: The impression copings in



Figure 6: Uni-abutments were selected for construction of a screw-retained bridge

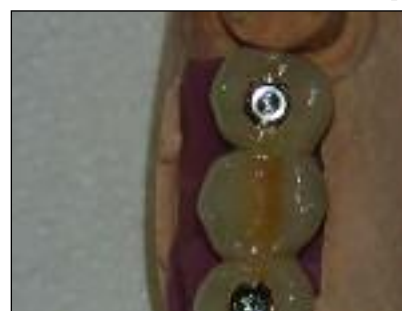

Figure 7: The implant-retained bridge

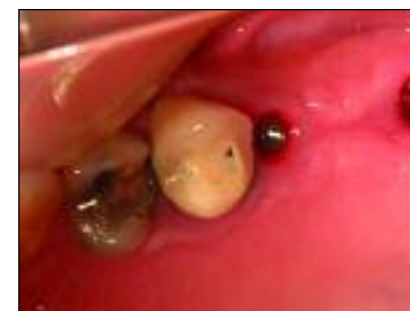

Figure 8: Two new uni-abutments were fitted

The patient was a 53-year-old male, a non smoker and with no significant medical history. He was an engineer by profession. He had lost his right first maxillary molar (RHS) around five years previously. Subsequently, he developed a large carious cavity in the maxillary second molar (RHS) and was referred to an endodontist for treatment. The endodontist felt this tooth would be unrestorable and advised that it be extracted. Faced with the prospect of a large gap in the posterior quadrant, the patient was referred to the practice in January 2005 for consultation regarding the upper right quadrant.

On examination, the patient demonstrated a fairly heavily restored dentition with one metal ceramic crown and five amalgam restorations in the maxilla and four gold crowns, (two of these teeth root treated) and three further restorations in the mandible (Figure 1). The most extensive restorative work was in the posterior segments and there was evidence on the teeth of a bruxing habit.

Figure 2 shows the DPT of the patient at presentation. The periapical radiolucency associated with the mesio-buccal and palatal roots may be seen. Figure 3 shows a digital periapical image of the upper

right second molar and upper right second pre-molar, where the extent of the decay in the maxillary second molar is seen more clearly.

The prospective treatment options were offered to the patient. They included:

- Extraction and live with the space or;
- Restore the space with a removable or fixed prosthesis.

The patient wished to have a fixed prosthesis and, therefore, an implant-retained bridge was chosen as the most suitable option. Studying the RHS maxillary sinus, there appeared to be adequate bone mesially and distally to the largest expansion of the sinus, which was primarily centred above the maxillary first molar site. The implant position were planned either side of this dip in an effort to avoid a sinus elevation.

#### Bruxing habit

Impressions were made, a face bow recorded, and the laboratory asked to create a wax up of three teeth and a surgical stent. Because of the bruxing habit, we requested the wax up and the final teeth to have a reduced occlusal table and be of pre-molar dimensions. At the start of February 2005, the right maxillary second molar was sectioned and carefully extracted, using periostomes

and luxators. The patient was reviewed one week later and healing had been uneventful. A pre-operative appointment was made for the end of March when two further periapical radiographs were taken prior to the selection of the implants (Figure 4).

Two Astra Osseospeed implants were selected – a 5.0mm diameter for the most posterior site and a 4.0mm diameter for the anterior site. A two-stage surgical procedure was planned, and surgical placement of the implants was carried out at the beginning of April 2005.

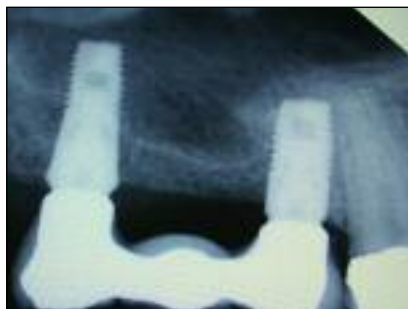
The second stage surgery was performed two and a half months after implant placement. Head-of-implant impressions followed this three weeks later. Figure 5 shows the impression copings in situ. Once the model had been cast with the appropriate replicas, two 20-degree taper uni-abutments were selected for construction of a screw-retained bridge (Figure 6). Figure 7 demonstrates the implant-retained bridge on the model.

The next appointment was the fit stage, where two new uni-abutments were fitted (Figure 8) and the bridge attached with two bridge screws, the screw heads covered with cotton wool and the screw hole filled with

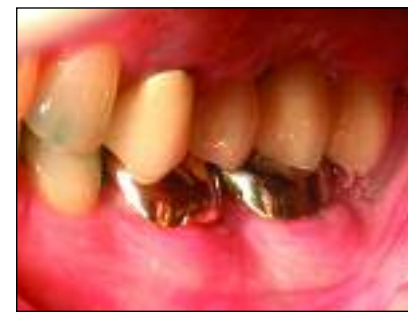
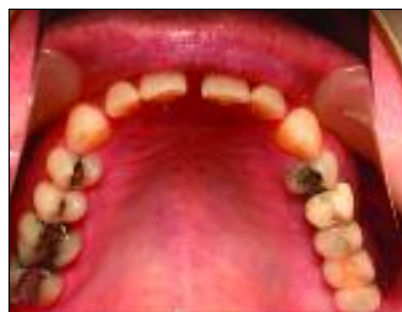
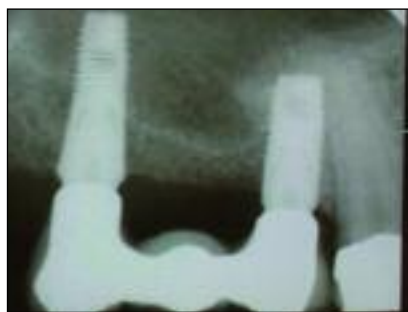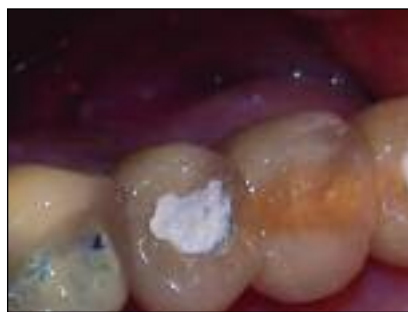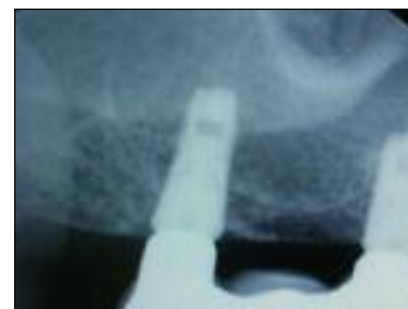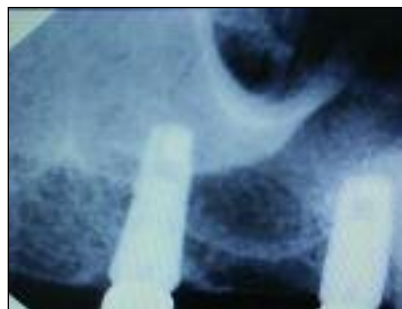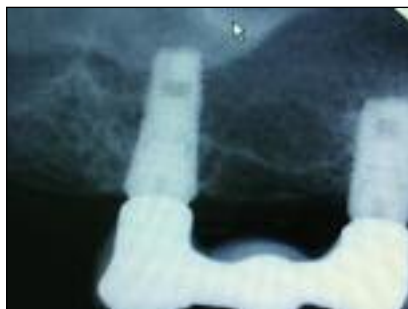Figure 9: The bridge attached with temporary restorative material covering the screw heads. Figure 10: An anteroposterior radiograph was taken of the implants at fit stage and the occlusion examined and adjusted using Schimstock as the indicator.

Figure 11: The temporary restorative material was replaced with composite. Figure 12: The bridge in centric relation from the buccal aspect.



Figures 13-16: Radiographs at intervals up to March 2009.

a temporary restorative material (Figure 9). An anteroposterior (AP) radiograph was taken of the implants at fit stage (Figure 10) and the occlusion examined and adjusted, using Schimstock as the indicator.

The patient was reviewed at two weeks and three months, at the latter appointment the cotton wool and temporary restorative were changed and the temporary restorative replaced with composite (Figure 11). Figure 12 shows the bridge in centric relation from the buccal aspect. Figures 13 to 16 show radiographs at intervals up to March 2009.



Harry RBP Shiers BDS, MSc (implant dentistry), MGDS, MFDS, took his initial training in implants in 1989 with the Straumann Institute. He spent a year teaching undergraduates at The London Dental Hospital and since then has spent a year at the Eastman Dental Institute studying implants prior to completing the two-year part-time Master of Science in implant dentistry at Guy's Hospital London. He currently runs the Harcourt House Implant Referral Centre in the west end of London where he places implants for referring GPs.